

## Original

# Retrospective cohort clinical investigation of a dental implant with a narrow diameter and short length for the partial rehabilitation of extremely atrophic jaws

Paulo S. Maló<sup>1)</sup>, Miguel A. de Araújo Nobre<sup>2)</sup>, Armando V. Lopes<sup>1)</sup>, and Ana S. Ferro<sup>1)</sup>

<sup>1)</sup>Oral Surgery Department, Malo Clinic, Lisbon, Portugal

<sup>2)</sup>Research and Development Department, Malo Clinic, Lisbon, Portugal

(Received April 20, 2016; Accepted October 28, 2016)

**Abstract:** We investigated the short-term clinical outcomes of narrow-diameter short-length implants for the fixed-prosthetic partial rehabilitation of extremely resorbed jaws. Twenty-three patients requiring partial rehabilitations with narrow-platform short-length implants in any jaw were included in this study. In total, 30 implants 3.3 mm in diameter and 7 ( $n = 15$  implants) or 8.5 ( $n = 15$  implants) mm in length were inserted. The primary outcome measure was implant cumulative survival rate (CSR); the secondary outcome measures were marginal bone resorption at 1 and 3 years and the incidence of biologic and mechanical complications. Five patients (21.7%) with six implants (20%) were lost to follow-up. Two implants failed in two patients, yielding a CSR at 3 years of follow-up of 93.4%. The average (standard deviation) marginal bone resorption was 1.34 mm (0.95 mm) after the first year and 1.38 mm (0.78 mm) after the third year. Biologic complications occurred in three patients; mechanical complications occurred in three patients. Despite the limitations of the study, our findings show that the use of new narrow-diameter short-length implants for the rehabilitation of extremely atrophic regions is viable in the short-term, and can be considered a treatment alternative in extremely resorbed jaws.

Keywords: implantology; implant design; implant survival; narrow diameter implant; short dental implant; atrophic jaw.

---

## Introduction

Implant-supported rehabilitations rely on the concept of osseointegration, specifically at the anchorage of endosseous implants in bone (1-5). The rehabilitation of atrophic jaws poses a serious challenge because of limitations in bone quantity (volume and width) and, in this context, narrow-diameter or short-length implants represent a treatment alternative for rehabilitation (2,6).

The use of narrow-diameter and short-length implants is discouraged given the potential negative impact on these types of implant that loading can exert. Biomechanical analyses have shown that narrow diameter implants have lower stability (compared with implants with a regular platform; 7), an increased probability of fracture based on the results of standardized fatigue testing (8) and finite-element analysis (9), and increased magnitudes of stress and strain (10). Similarly, the use of short dental implants has been discouraged given the potential biomechanical risk when combined with poor bone quality and high occlusal loads (3).

Few clinical studies have evaluated the outcomes of short-length or narrow-diameter dental implants. The use of short implants (7-8.5 mm) has been associated with lower success rates (11), which were nevertheless comparable to those of implants placed in vertically augmented bone (12). In the literature, the reported survival rates for short dental implants range widely (between 88% and 100%; 2,13,14). Conversely, results from previous studies on narrow-diameter implants

---

Correspondence to Dr. Miguel A. de Araújo Nobre, Research and Development Department, Malo Clinic, Avenida dos Combatentes 43, piso 11, Ed. Green Park, 1600-042, Lisbon, Portugal  
Fax: +351-217-266-965 E-mail: mignobre@gmail.com

Color figures can be viewed in the online issue at J-STAGE.  
doi.org/10.2334/josnusd.16-0321  
DN/JST.JSTAGE/josnusd/16-0321

indicate a survival rate of between 96% and 99.4% with follow-ups of 1-5 years and irrespective of the surgical approach used (two-stage surgical approach, one-stage surgical approach, or immediate-function approach; 6,15-17). However, the limited sample size (12,17) and follow-up duration (12,15) of these studies may increase potential bias, obscuring the true outcomes of fixed-prosthetic rehabilitations supported by narrow-diameter or short-length implants.

Developments in surgical techniques and macro (body) and micro (surface) implant design necessitated a re-evaluation of previous results, which indicated that short implants can support most prosthetic restorations adequately (2,14) provided that a careful analysis of biomechanical risk factors is performed beforehand (13). The combination of these two characteristics (narrow diameter and short length) in one implant reflects the demand for the rehabilitation of extremely atrophic jaws with the most challenging conditions in which an implant could not otherwise be inserted without bone grafting, osteodistraction, or nerve transposition.

Studies that evaluate the two characteristics (narrow diameter and short length) in the same implant are scarce. The aim of this retrospective clinical study was to assess the short-term clinical outcomes of an implant body with a narrow diameter and short length for the partial rehabilitation of extremely atrophic edentulous jaws.

## Materials and Methods

This study was performed at Malo Clinic, Lisbon, Portugal. It was conducted in accordance with the Declaration of Helsinki, and with the written informed consent of the participants. The study was approved by an independent ethics committee (Ethical Committee for Health; Authorization Number 005/2013).

We conducted a chart review of patients meeting the inclusion criterion. The inclusion criterion was the need for partial rehabilitation with narrow-diameter short-length implants in either jaw: the implant areas had to present a thin alveolar crest or reduced inter-radicular bone sufficient to receive an implant with a diameter of at least 3.3 mm and a residual bone volume sufficient to receive an implant of at least 7 mm in length. Patients were excluded if they were undergoing concomitant radiotherapy or chemotherapy, past bone grafting or bone grafting during implant treatment.

Twenty-three patients (20 women and three men) with an average age of 50.9 years (range: 27-70 years), treated consecutively between August 2010 (first implant insertion) and November 2012 (last implant insertion), met the inclusion criterion. Nine patients were systemi-

cally compromised (three had rheumatologic diseases, three had cardiovascular conditions, two had oncologic conditions, and one had diabetes; one presented with two conditions), and four patients were smokers.

The implant (NobelSpeedy; Nobel Biocare AG, Gothenburg, Sweden) had the following characteristics (18): a straight body, short collar, narrow implant apex, and diameter of 3.3 mm. The implant had a moderately rough surface generated by anodic oxidation (TiUnite) and a groove.

Regarding the surgical techniques used, one implant was inserted using the immediate-function approach, whereas the remaining implants ( $n = 29$ ) were inserted using the delayed-loading technique (implant insertion and abutment connection in the same surgical step, followed by connection of the prosthesis after 4 months). The surgical and prosthodontic treatments were performed by the same team. Surgery was performed under local anesthesia using mepivacaine hydrochloride with epinephrine 1:100,000 (Scandinibsa 2%; Inibsa Laboratory, Barcelona, Spain). Sedation prior to surgery was performed using diazepam (Valium 10 mg; Roche Farmaceutica Quimica, Ltd., Amadora, Portugal). Antibiotherapy (amoxicillin 875 mg and clavulanic acid 125 mg; Labesfal Farma, Campo de Besteiros, Portugal) was performed 1 h before surgery and every 8 h post-surgery over 4 days. Corticosteroid medication (prednisone; Meticorten, 5 mg, Schering-Plough Farma, Ltd., Agualva-Cacém, Portugal) was given in regression mode (15 mg per-operatively, 10 mg on the 1st and 2nd days post-operatively, and 5 mg on the 3rd and 4th days post-operatively) to control the inflammatory response. Anti-inflammatories were administered twice (every 12 h) on the 5th day post-operatively (ibuprofen, 600 mg; Ratiopharm, Ltd., Carnaxide, Portugal). Analgesics were administered per-operatively, and on the first 3 days if necessary (clonixine, Clonix 300 mg; Janssen-Cilag Farmacêutica, Ltd., Barcarena, Portugal). Antacid medication was given per- and post-operatively every day until the 6th day (omeprazole, 20 mg; Generis Farmacêutica, S.A., Sintra, Portugal).

The insertion of the implants followed standard procedures (2). The drilling sequence was modified to underprepare the implant site to achieve maximal apical anchorage. Countersinking was not performed for marginal bone preservation. The implant neck was positioned at the coronal marginal crest level. A clinical situation is illustrated in Figs. 1 and 2. The patient was rehabilitated through an immediate-function approach, and received an acrylic-resin restoration on the day of surgery. After 4-6 months, the definitive abutments (Multi-unit Abut-



**Fig. 1** Photograph illustrating the implant (3.3 mm wide and 8.5 mm long).

ment; Nobel Biocare AG) were attached (when used), an impression was made using silicone material (Elite HD+; Zhermack, Rovigo, Italy), and screw-retained metal-ceramic crowns/ fixed partial prostheses or cement-retained ceramic crowns were connected as definitive restorations. On the definitive restorations, the occlusion mimicked that of the natural dentition.

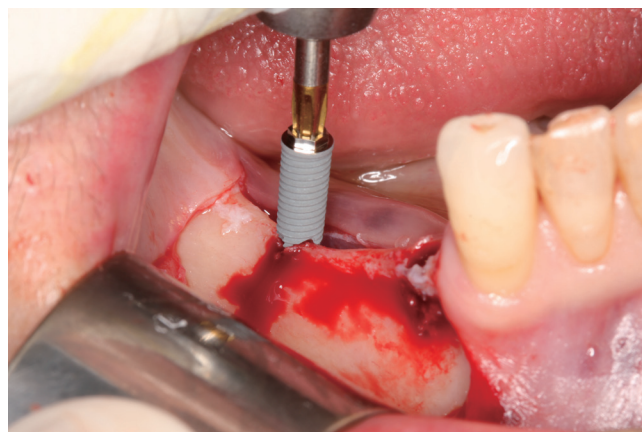
The patients were enrolled in a maintenance program. They were advised in the first 2 months post-surgery to adopt a soft food diet. At 10 days post-surgery, suture removal was performed and implant stability was evaluated. The evaluation was repeated at 2, 4, and 6 months post-surgery. Thereafter, the patients were examined every 6 months for the first year and yearly thereafter.

### Primary outcome measures

The primary outcome measures were prosthetic and implant survival based on function. Implants were considered successful if they: fulfilled their function as a support for the restoration; were stable when manually tested (with the exception of single crowns, prostheses were removed and individual implant stability was evaluated manually by applying lateral forces to the implants); lacked persistent infection; lacked radiolucent areas around the implants; had a good esthetic outcome; allowed construction of an implant-supported restoration that was comfortable and suited to hygienic maintenance.

### Secondary outcome measures

The secondary outcome measures were marginal bone resorption and the incidence of mechanical and biologic complications. Periapical radiographs (Eastman Kodak Company, Rochester, NY, USA) were performed at implant insertion and 1 and 3 years post-loading. A conventional radiograph holder (Super-Bite; Hawe Neos Dental, Bioggio, Switzerland) was used, with its posi-



**Fig. 2** Intra-oral per-operative photograph at implant insertion. Note the very thin crestal ridge in the area to be rehabilitated (lower left from the first premolar to the first molar).

tion manually adjusted to position the film as parallel to the implant as possible. The inclusion or exclusion of radiographs for evaluation was based on the clarity of the implant threads: clear vision of the implant thread guaranteed sharpness and alignment of the radiographic beam with the implant axis. The reference point for the reading was the implant platform, i.e., the horizontal interface between the implant and the abutment. Marginal bone resorption was defined as the difference between bone levels at baseline and at 1 and 3 years. An assessor blinded to the outcomes examined all implant radiographs. Each periapical radiograph was scanned at 300 dots per inch using a scanner (HP Scanjet 4890; HP Portugal, Paço de Arcos, Portugal). Marginal bone level assessments were performed using image analysis software (ImageJ version 1.40g for Windows; National Institutes of Health, Bethesda, MD, USA).

The complications assessed in this study were mechanical (any loosening or fracture of a prosthodontic component of the restoration); and biologic (pain, soft-tissue inflammation, fistula formation, or peri-implant pathology).

Descriptive statistics were used to classify the variables of interest. Implant survival was analyzed through life-table analysis. Statistics were performed using the Statistical Package for Social Sciences (SPSS version 18; IBM Corporation, Armonk, NY, USA).

## Results

In total, 30 implants were placed: 15 implants 7 mm in length, and 15 implants 8.5 mm in length. Twenty-nine rehabilitations were connected to the 30 study implants: 22 single-teeth rehabilitations (maxilla: three rehabilitations, all screw-retained metal-ceramic crowns; mandible: 19 rehabilitations, 18 screw-retained metal-

**Table 1** Distribution of the narrow-diameter short-length implants in the oral cavity

Location/Outcome	Tooth position														Total
	17	16	15	14	13	12	11	21	22	23	24	25	26	27	
Maxilla	17	16	15	14	13	12	11	21	22	23	24	25	26	27	Total
Placed	0	0	2	0	0	0	1	1	0	0	0	1	0	0	
Failed	0	0	0	0	0	0	0	0	0	0	0	0	0	0	0
Mandible	47	46	45	44	43	42	41	31	32	33	34	35	36	37	Total
Placed	2	7	3	0	0	0	0	0	0	0	1	8	4	0	
Failed	0	0	1	0	0	0	0	0	0	0	0	1	0	0	2

**Table 2** Cumulative success rate of narrow-diameter short-length implants

Duration	Total	Failed	Lost to follow-up	Not yet due	SR	CSR
Insertion-6 months	30	1	0	0	96.7%	96.7%
6 months-1 year	29	1	4	0	96.4%	93.4%
1-2 years	24	0	2	0	100%	93.4%
2-3 years	22	0	0	0	100%	93.4%

SR: Survival rate; CSR: Cumulative survival rate.

**Table 3** Failure pattern of narrow-diameter short length implants

Sex	Age	Implant position	Rehabilitation	Type of opposing dentition	Time of loss in months	Observations
1 Female	55	45	Partial	Natural teeth	5 months	Smoker
2 Female	52	35	Single teeth	Fixed prosthesis over natural teeth	9 months	

**Table 4** Evaluation of marginal bone resorption (mm) at 1 and 3 years of follow-up for narrow-diameter short-length implants

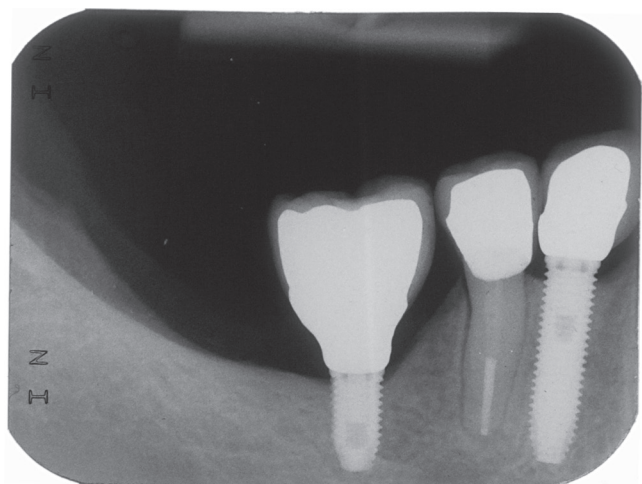
	1 year		3 years	
	Mean (mm) [95% confidence interval]	Standard deviation (mm)	Mean (mm) [95% confidence interval]	Standard deviation (mm)
	1.34 [0.91-1.78]	0.95	1.38 [1-1.77]	0.78
Number	21		18	
Frequencies	<i>n</i>	%	<i>n</i>	%
0 mm	0	0	0	0
0.1 to -1 mm	9	42.9	8	44.4
1.1 to -2 mm	8	38.1	7	38.9
2.1 to -3 mm	3	14.3	2	11.1
>-3 mm	1	4.8	1	5.6

ceramic crowns and one cement retained ceramic crown); and seven partial rehabilitations (maxilla: one rehabilitation of two study implants in conjunction with another implant; mandible: six rehabilitations, three rehabilitations of three study implants in conjunction with three other implants, all screw-retained metal-ceramic fixed partial prostheses). The types of opposing dentition used were removable denture (one restoration in one patient), natural teeth (17 restorations in 13 patients), fixed prosthesis over natural teeth (five restorations in five patients), and implant-supported fixed prostheses (six restorations in five patients). The implant distribution in terms of location in the jaws is presented in Table 1.

Five patients (21.7%) with six implants (20%) were lost to follow-up: three during the first year and two during the second year. Two patients lost two implants, yielding

a cumulative survival rate of 93.4% at 3 years (Table 2), equating to a 96% survival rate for non-smokers (one implant failure/25 implants) and an 80% survival rate for smokers (one implant failure/five implants). Detailed characteristics of the two failed implants are given in Table 3. Both implants were lost before the connection of the prosthesis: one was lost at 5 months of follow-up (in a smoker), and the other was lost at 9 months of follow-up but revealed signs of breakdown at 5 months and, therefore, was left unloaded (in a non-smoking patient).

The average (standard deviation) marginal bone resorption was 1.34 mm (0.95 mm) after the 1st year and 1.38 mm (0.78 mm) after the 3rd year (Table 4). Representative radiographs of a patient rehabilitated with one implant with a narrow diameter and a short length are presented in Figs. 3 and 4.



**Fig. 3** Patient with a single-tooth rehabilitation (position #46) supported by a narrow-diameter short-length implant 3.3 mm in diameter and 7 mm in length at 1 year of follow-up.

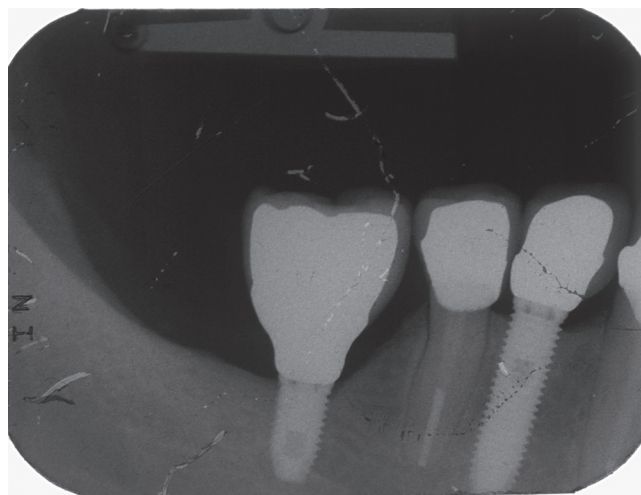
Biologic complications occurred in three patients (13%) and four implants (13.3%), consisting of infections (peri-implant pockets > 4 mm of depth with suppuration). The occurrences were addressed and resolved with systemic antibiotics and without surgical treatment (two patients with three implants), with or surgical intervention together with antibiotics and anti-inflammatory medication (one patient with one implant).

Mechanical complications occurred in three patients (13%) with three implants (10%), consisting of: prosthesis decementation in one patient with natural teeth as the opposing dentition suspected of being a heavy bruxer; abutment-screw loosening in one patient with a fixed prosthesis with natural teeth as the opposing dentition; and fracture of a provisional acrylic-resin prosthesis (a fracture line between crowns in positions #34 and #35) in one patient with an implant-supported prosthesis as the opposing dentition. These complications were resolved by mending the prosthesis (one patient), retightening the abutment screw (one patient), cementing the prosthesis (one patient), and adjusting occlusion (all patients).

### Discussion

The rehabilitation of extremely atrophic jaws using implants with a narrow platform (3.3 mm) and short length (7-8.5 mm) yielded an estimated short-term survival rate of 93.4% in this preliminary report. The limitations of this study included its small sample size, examination of patients attending a single clinical center involved, and a loss-to-follow-up rate exceeding 20%; thus, the generalizability of our results is limited.

The context for using these implants falls within the scope of partial fixed prosthetic rehabilitation procedures



**Fig. 4** Patient with a single-tooth rehabilitation (position #46) supported by a narrow-diameter short-length implant 3.3 mm in diameter and 7 mm in length at 3 years of follow-up.

in a very low residual bone volume. To date, published studies have examined the outcomes of fixed prosthetic rehabilitations using either narrow-diameter implants with longer lengths or short-length implants with wider platforms than those used in this study, in which a narrow diameter and short length were combined in one implant. Regarding the use of longer implants with a narrow diameter, previous studies have reported survival rates of 95.3% at 10 years of follow-up (a retrospective study using one-stage surgery; 19) and 96% at 5 years of follow-up (a prospective study using two-stage surgery; 17). In a systematic review investigating the success of narrow-diameter implants, Klein et al. (20) reported success rates of between 91.4 and 97.6%, with no significant differences in survival between narrow- and regular-diameter implants. In another systematic review, Sierra-Sánchez et al. (21) concluded that narrow-diameter implants were a predictable treatment option with clinical results comparable to those obtained with implants of larger diameter.

This comparability partly extends to short-length implants, as reported in recent systematic reviews and meta-analyses. Regarding short-term outcomes, Annibali et al. (22) reported a 99.1% cumulative survival rate. Al-Ansari (23) reported a 94.1% survival rate for single teeth supported by short-length dental implants, whereas a quantitative analysis determined that implants inserted into the mandible and with a length of <8 mm were predictors for implant failure. Our study, in which the majority of implants were inserted in the mandible for single-crown rehabilitation, showed similar outcomes to this study: both implant failures occurred in the mandible and with an implant 7 mm in length. Furthermore, a previous prospective study reported a 95% cumulative

survival rate for short implants (7 mm in length) in the rehabilitation of atrophic posterior jaws (24).

The deleterious effect of smoking on implant survival was noted in this study, equating to a 16% difference between smokers (80%) and non-smokers (96%). A recent meta-analysis (25) investigating the risk factors for early implant failure reported that smoking habits (odds ratio: 1.7), implants shorter than 10 mm (odds ratio: 1.6), and implants inserted into the maxilla (odds ratio: 1.3) were the main significant factors. The presence of these significant factors (smoking habits and short dental implants) may in part explain the early implant failures that occurred in this study. Furthermore, the opposing restorations influenced the clinical outcome: a fixed prosthesis was the opposing dentition in one of the two implant failures and two of the three patients with mechanical complications, emphasizing the necessity of closely monitoring the occlusion during the follow-up of implant restorations.

The marginal bone resorption recorded at 1 year in this study was comparable to that reported for narrow-diameter (with a greater length; 20) and short-length (with a larger diameter) implants inserted in areas with more favorable conditions (in the presence of higher bone quality or quantity; 24,26). In the studies referenced, the marginal bone loss at 1 year was between 0.95 mm (24) and 1.27 mm (26) for short-length implants with a regular platform, and 1.16 mm (20) for narrow-diameter implants with a greater length. Considering the challenging conditions for implant insertion in this study, a difference of 0.07 mm in marginal bone resorption between the narrow-diameter short-length implants and short-length implants with a regular platform (24) may be negligible.

The results of this study support the hypothesis that narrow-diameter short-length implants can be used in fixed prosthetic partial rehabilitations in extremely atrophic jaws with a predictable and favorable short-term outcome. This approach is justified when considering the more technically difficult and time-consuming alternatives, such as implants inserted into grafted bone (27), osteodistraction, or inferior alveolar nerve transposition (28) prior to implant insertion. A recent systematic review of randomized controlled trials (27) assessing the effects of bone augmentation versus no augmentation reported that there was insufficient evidence to support differences in prosthetic or implant failure rates between short implants placed without the sinus lift procedure and longer implants placed with the sinus lift procedure; nevertheless, an increase in the incidence of complications at the treated sites was evident with the sinus lift

approach. A prospective study evaluated the incidence of neurosensory disturbance and the cumulative survival and success rates of implants inserted in conjunction with inferior alveolar nerve transposition (28): despite the high survival and success rates, neurosensory disturbance was experienced by 21% of patients (4/19 patients) following the nerve transposition procedure, which remained unresolved in one patient after the study's completion.

The patients were followed for 3 years after loading in the current study. Studies with larger samples, a longer duration of follow-up, and comparing different rehabilitation modalities (for example, longer implants with a larger diameter inserted into grafted bone) should be performed to assess the mid- and long-term outcomes of the rehabilitations performed under the conditions described in this study. Despite the limitations of this study, our results suggest that new narrow-diameter short-length implants are suitable for the prosthetic rehabilitation of extremely atrophic sites in both jaws, and yield a good survival rate and low marginal bone resorption in the short-term. Considering the context of use, these implants may represent a valuable treatment alternative for the surgeon before opting for more challenging, technically and biologically demanding rehabilitation procedures.

### Acknowledgments

This study was supported by grant from Nobel Biocare Services AG (2014-1258). The authors would like to thank Mrs. Andreia de Araújo for all the help in data management.

### Conflict of interest

Professor Paulo Maló is currently a consultant for Nobel Biocare AG. The remaining authors received previous scientific grants from Nobel Biocare Services AG.

### References

1. Albrektsson T, Brånemark PI, Hansson HA, Lindström J (1981) Osseointegrated titanium implants. Requirements for ensuring a long-lasting, direct bone-to-implant anchorage in man. *Acta Orthop Scand* 52, 155-170.
2. Adell R, Lekholm U, Rockler B, Brånemark PI (1981) A 15-year study of osseointegrated implants in the treatment of the edentulous jaw. *Int J Oral Surg* 10, 387-416.
3. Brånemark PI, Adell R, Albrektsson T, Lekholm U, Lundkvist S, Rockler B (1983) Osseointegrated titanium fixtures in the treatment of edentulousness. *Biomaterials* 4, 25-28.
4. Brånemark PI (1983) Osseointegration and its experimental background. *J Prosthet Dent* 50, 399-410.
5. Parel SM, Brånemark PI, Jansson T (1986) Osseointegration in maxillofacial prosthetics. Part I: intraoral applications. *J Prosthet Dent* 55, 490-494.

6. Degidi M, Piattelli A, Carinci F (2008) Clinical outcome of narrow diameter implants: a retrospective study of 510 implants. *J Periodontol* 79, 49-54.
7. Winkler S, Morris HF, Ochi S (2000) Implant survival to 36 months as related to length and diameter. *Ann Periodontol* 5, 22-31.
8. Allum SR, Tomlinson RA, Joshi R (2008) The impact of loads on standard diameter, small diameter and mini implants: a comparative laboratory study. *Clin Oral Implants Res* 19, 553-559.
9. Akça K, Cehreli MC, Iplikçioğlu H (2003) Evaluation of the mechanical characteristics of the implant-abutment complex of a reduced-diameter Morse-taper implant. A nonlinear finite element stress analysis. *Clin Oral Implants Res* 14, 444-454.
10. Cehreli MC, Akça K (2004) Narrow-diameter implants as terminal support for occlusal three-unit FPDs: a biomechanical analysis. *Int J Periodontics Restorative Dent* 24, 513-519.
11. Lemos CA, Ferro-Alves ML, Okamoto R, Mendonça MR, Pellizzer EP (2016) Short dental implants versus standard dental implants placed in the posterior jaws: a systematic review and meta-analysis. *J Dent* 47, 8-17.
12. Nisand D, Picard N, Rocchietta I (2015) Short implants compared to implants in vertically augmented bone: a systematic review. *Clin Oral Implants Res* 26, Suppl 11, 170-179.
13. Davarpanah M, Martinez H, Tecucianu JF, Celletti R, Lazzara R (2000) Small-diameter implants: indications and contraindications. *J Esthet Dent* 12, 186-194.
14. Vigolo P, Givani A, Majzoub Z, Cordioli G (2004) Clinical evaluation of small-diameter implants in single-tooth and multiple-implant restorations: a 7-year retrospective study. *Int J Oral Maxillofac Implants* 19, 703-709.
15. Hallman M (2001) A prospective study of treatment of severely resorbed maxillae with narrow nonsubmerged implants: results after 1 year of loading. *Int J Oral Maxillofac Implants* 16, 731-736.
16. Zinsli B, Sägeser T, Mericske E, Mericske-Stern R (2004) Clinical evaluation of small-diameter ITI implants: a prospective study. *Int J Oral Maxillofac Implants* 19, 92-99.
17. Comfort MB, Chu FC, Chai J, Wat PY, Chow TW (2005) A 5-year prospective study on small diameter screw-shaped oral implants. *J Oral Rehabil* 32, 341-345.
18. Maló P, Nobre Mde A, Petersson U, Wigren S (2006) A pilot study of complete edentulous rehabilitation with immediate function using a new implant design: case series. *Clin Implant Dent Relat Res* 8, 223-232.
19. Maló P, de Araújo Nobre M (2011) Implants (3.3 mm diameter) for the rehabilitation of edentulous posterior regions: a retrospective clinical study with up to 11 years of follow-up. *Clin Implant Dent Relat Res* 13, 95-103.
20. Klein MO, Schiegnitz E, Al-Nawas B (2014) Systematic review on success of narrow-diameter dental implants. *Int J Oral Maxillofac Implants* 29, S43-54.
21. Sierra-Sánchez JL, Martínez-González A, García-Sala Bonmatí F, Mañes-Ferrer JF, Brotons-Oliver A (2014) Narrow-diameter implants: are they a predictable treatment option? A literature review. *Med Oral Patol Oral Cir Bucal* 19, e74-81.
22. Annibali S, Cristalli MP, Dell'Aquila D, Bignozzi I, La Monaca G, Pilloni A (2012) Short dental implants: a systematic review. *J Dent Res* 91, 25-32.
23. Al-Ansari A (2014) Short implants supporting single crowns in atrophic jaws. *Evid Based Dent* 15, 85-86.
24. Maló P, Nobre Md, Lopes A (2011) Short implants in posterior jaws. A prospective 1-year study. *Eur J Oral Implantol* 4, 47-53.
25. Manzano G, Montero J, Martín-Vallejo J, Del Fabbro M, Bravo M, Testori T (2016) Risk factors in early implant failure: a meta-analysis. *Implant Dent* 25, 272-280.
26. Maló P, de Araújo Nobre M, Rangert B (2007) Short implants placed one-stage in maxillae and mandibles: a retrospective clinical study with 1 to 9 years of follow-up. *Clin Implant Dent Relat Res* 9, 15-21.
27. Esposito M, Felice P, Worthington HV (2014) Interventions for replacing missing teeth: augmentation procedures of the maxillary sinus. *Cochrane Database Syst Rev* 5, CD008397.
28. Ferrigno N, Laureti M, Fanali S (2005) Inferior alveolar nerve transposition in conjunction with implant placement. *Int J Oral Maxillofac Implants* 20, 610-620.